


Sono-Instruments® Surgical Technique

Percutaneous sonography-guided
carpal tunnel and trigger finger release

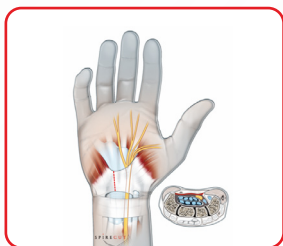

SPIRE CUT



INDICATIONS

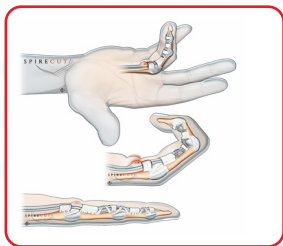
The Sono-Instruments® are intended to be used for adult common upper extremity affections :



1

Carpal tunnel syndrome

(percutaneous release of the transverse carpal ligament or flexor retinaculum)



2

Trigger finger/thumb

(percutaneous release of annular pulley(s), in particular the A1 pulley, with or without adjacent ganglion)

The Sono-Instruments® are presented in a single-use sterile kit, along with a probe helping in the dissection of the tissues and, at the end of the procedure, allowing to make sure that the surgical release is complete.

PERCUTANEOUS SURGERY BENEFITS

Spirecut's Sono-Instrument® is a simple and efficient solution to treat carpal tunnel and trigger finger :



Safe surgery, as the patented design of the Sono-Instrument® enhances the visibility of the cutting extremity during the release under ultrasound imaging



Truly percutaneous surgery : no skin incision, no external blood loss, no stitches, no dressing. This allows simultaneous treatment of carpal tunnel and of multiple trigger fingers and/or bilateral surgery



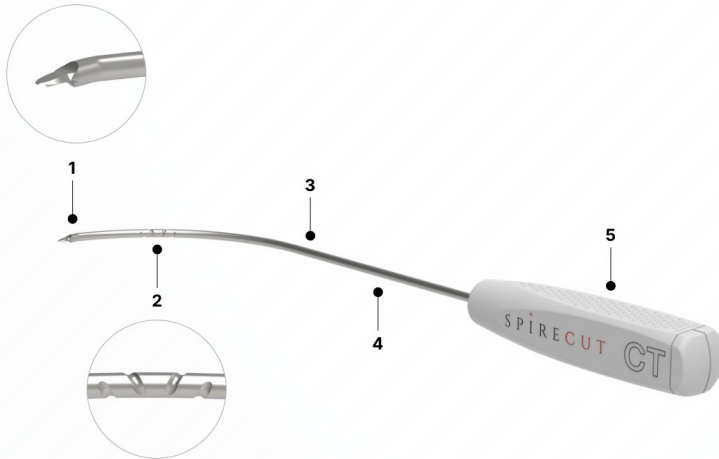
Quick surgery, performed under local anaesthesia, with minimal instrumentation



Early return of patients to daily light activities

SPIRECUT'S SONO-INSTRUMENTS®

Carpal Tunnel Sono-Instrument®



1. Cutting extremity

Cutting extremity allowing release in the plane chosen by the surgeon, safe for neighbouring tendons/ nerves/ vessels, with lateral flanges enhancing the echogenicity

2. Spiral groove

Spiral groove facilitating the visualization of the Sono-Instrument® under sonography and providing information about rotatory alignment

3. Rod design

Special design of the rod, adapted to the anatomy of the adult carpal tunnel (carpal tunnel instrument) or to the flexor digital sheath (trigger finger instrument)

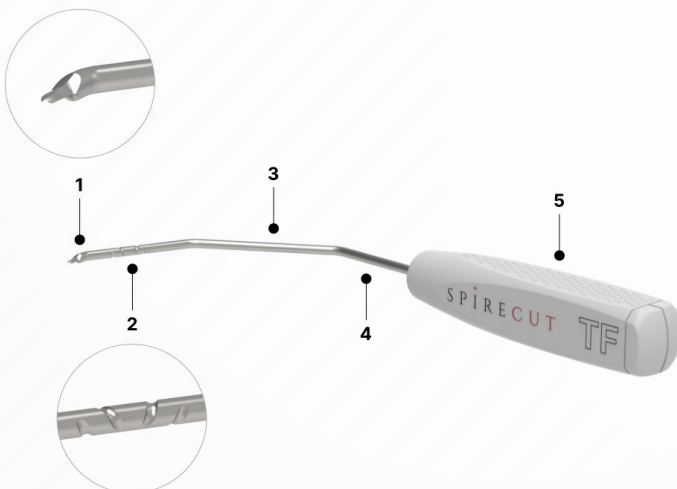
4. Rod diameter

1.5mm diameter rod, allowing insertion through the skin by a puncture made by a 14 Gauge IV catheter

5. Handle

Handle, allowing firm non-slip grip of the Sono-Instrument® and the maintain of its orientation throughout the whole procedure of release

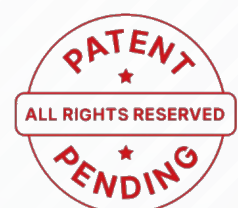Trigger Finger Sono-Instrument®



Probe



1.5mm diameter smooth probe, facilitating the dissection and allowing at the end of the procedure to check the completeness of the release (note : in tight trigger fingers, there may be not enough space to use the probe at the begin of the procedure – use then directly the Sono-Instrument®)



PRECAUTIONS

The Sono-Instruments® are single-use sterile medical devices intended for mini-invasive hand surgery under sonography. SPIRECUT assumes that professional users have experience and knowledge of standard protocols regarding hand surgery and particularly in percutaneous release procedures under sonography. Furthermore, SPIRECUT declines any responsibility if the users have not followed lab manual-skills training with associated instrumentation prior to the procedure. Surgeons are advised to review the instructions for use before performing any surgery.

In case of any doubt in identification of the anatomical structures or poor visibility of the Sono-Instrument® during the operation, always convert to open surgery (or stop the surgery).

CONTRA-INDICATIONS

Do not use SPIRECUT'S Sono-Instruments®

- in direct contact with the central circulatory system or central nervous system,
- in children, dwarf patients or in case of small size hand/carpal tunnel/finger-thumb,
- if there is a history of a previous infection, as the infection could have caused fibrosis, or as the operation can re-activate the infection, causing delayed healing and/or severe complications,
- in case of active or past infections, because the infection may be spread to healthy tissues and made worse by the operation,
- in conditions that tend to limit the patient's ability or willingness to understand per or postoperative recommendations during the healing period,
- for surgeries other than those indicated or at another anatomical location,
- in case of known allergic reaction to metals,
- in case of known clinical risks associated to the use of Sono-Instruments® outweighing the expected clinical benefits,
- in case of anatomical abnormalities affecting the flexor digital sheath, digital nerves/vessels, median nerve, median nerve artery, flexor tendons, wrist bones or in case of local tumors or other conditions increasing the risk of an iatrogenic lesion ; a trigger finger of long evolution, with stiffness of the proximal interphalangeal joint constitutes a relative contra-indication as it could be better treated by open surgery with removal of a superficialis tendon slip,
- in case of an alteration of the coagulation with significant risk of per/postoperative bleeding,
- in case of any contra-indication to anesthesia, whether local, regional or general,
- in case of insufficient sonographic identification of the operated tissues or insufficient experience of the user in sonography,
- in case of neuro-vascular structures in the zone of intended release, like may be seen in anatomical variations or vessel dilatation like seen in case of an arterio-venous fistula,
- in case the physician has insufficient experience in hand surgery and particularly deficient knowledge of hand anatomy, including anatomical variants,
- in case of tissue adhesions which may potentially compromise the safe and precise introduction of the probe and then of the Sono-Instrument,
- in case of a previous surgical attempt to treat the condition, for example a persistent disease after previous open, endoscopic or percutaneous procedure, or a recurrence of the condition with persistent or recurrent symptoms,
- in case of a previous fracture or dislocation in the operated area or any affection causing malalignment or distortion of the local skeleton, due to trauma, arthritis or other causes,
- for the carpal tunnel syndrome, in case of severe median nerve dysfunction requiring microsurgical epineurotomy, or if the nerve dysfunction has another cause than an idiopathic compression syndrome, like a canalar mass (ganglion, tumor, foreign body, or other space-occupying diseases),
- in case of the devices are plastically deformed, broken or fall down. If the event happens throughout surgical procedure, remove the instrument and all the fragments immediately.

In general, all other contra-indications mentioned for endoscopic release of carpal tunnel or trigger finger/thumb are valid for percutaneous release using Spiirecut's Sono-Instruments®.

SURGICAL TECHNIQUE

The Sono-Instruments® (SI) are intended to be used solely in a medical facility, under sterile conditions, by experienced clinicians, usually surgeons, rheumatologists or radiologists, with sufficient knowledge of hand anatomy, hand surgery and sonography. Training during hands-on workshops and/or watching experienced physicians performing the operation is strongly recommended before doing the first clinical cases. Sono-Instruments® are indicated only for patients suffering of either carpal tunnel (SI-CT) or trigger finger/trigger thumb syndrome (SI-TF).

Surgical set up

The patient is comfortably installed in supine position. The operation can be performed under regional or general anesthesia, but local anesthesia is preferred because of decreased morbidity, technique better adapted to ambulatory surgery, dynamic peri-operative testing (before, during and after the release) of actively movable structures like the flexor tendon(s) in carpal tunnel and trigger finger/thumb ; in addition, under local anesthesia, the occurrence of dysesthesia pain during the procedure may alert the clinician to the vicinity of a nerve.

The patient's arm rests on a lateral table. The surgeon sits in front of the operated hand, holding the Sono-Instrument® with his/her dominant hand and the sonographic probe with his/her non-dominant hand (the surgeon is therefore installed close to the head or close to the belly of the patient, depending on the side operated and on the laterality of the surgeon). The operation is usually performed without tourniquet. Avoiding a tourniquet has several advantages, including better visualization under sonography of pulsating arteries, and for the patient less pain and better muscular function for perioperative active mobilization. As the surgery is percutaneous, bleeding is usually minimal, even if the patient has decreased coagulation (significant alteration of the coagulation represents however a contra-indication to the operation). Finally, under sonography, bleeding does not alter the visibility of either anatomical structures or instrument.

Before disinfection, usually a first session of sonography takes place, to investigate the pathological condition(s) to be treated, the

neighboring anatomical structures, to make sure that there is no anatomical nor pathological condition contra-indicating the operation, and to verify under non-sterile conditions the general installation of the patient and of the sonography probe and screen, for the comfort of the patient, to evaluate the feasibility of the operation under local anesthesia, to assess the cooperation of the patient and the technical ease for the physician (figures 1, 2, 7, 8, 9 and 10).

The operated limb is then disinfected, and the sterility is maintained using disposable drapes. The surgical field should be relatively large. The clinician, under sterile conditions (sterile gown and gloves) obtains from the nurse the sterile material necessary for the operation: Sono-Instrument® and probe, syringe and needle for local anesthesia, (preferably a 10ml syringe, with either a 23 Gauge 25mm needle - trigger finger/thumb - or a 21 Gauge 50mm needle - carpal tunnel), an IV catheter to perforate the skin and the flexor tendon sheath or forearm aponeurosis (preferably a 14 Gauge intravenous catheter), sterile sonographic gel, sterile transparent cover for the sonographic probe, and sponges and material for the compressive dressing at the end of the operation. The clinician then covers in sterile conditions the sonographic probe with already some gel on it, avoiding any space containing air between the probe and the sterile transparent cover, so that there will be no interposition which would block the echos' transmission. A support allowing to hold the hand maybe helpful, allowing finger metacarpal-phalangeal hyperextension for trigger finger surgery. Alternatively thick sponges may be used to provide this support.

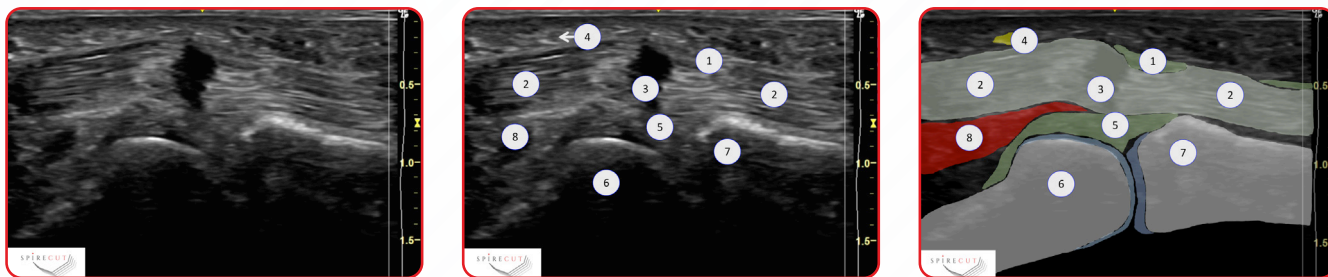

Figure 1 : Trigger thumb sonogram, longitudinal view : 1 : A1 annular pulley ; 2 : FPL ; 3 : FPL anisotropic artifact (frequently observed in case of triggering with impaired tendon excursion) ; 4 : Thumb radial digital nerve ; 5 : Palmar plate ; 6 : Head of first metacarpal ; 7 : Base of proximal phalanx ; 8 : FPB

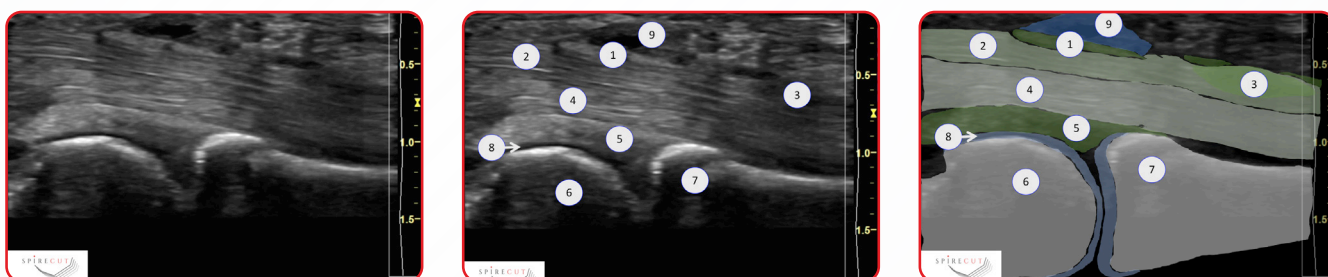

Figure 2 : Trigger digit (long finger), longitudinal view : 1 : Thickened A1 annular pulley ; 2 : FDS ; 3 : Nodule within FDS ; 4 : FDP ; 5 : Palmar plate ; 6 : Head of first metacarpal ; 7 : Base of proximal phalanx ; 8 : Hyaline cartilage of head of metacarpal bone ; 9 : Ganglion on A1 annular pulley

Trigger finger/thumb

Even if it's not mandatory, the use of a hockey stick sonographic probe is recommended because of the ease of its use in the finger.

The clinician repeats the pre-operative sonographic imaging of the limb, now under sterile conditions, to make sure that he/she can well identify the anatomical structures representing important landmarks (metacarpal-phalangeal joint, palmar surfaces of metacarpal and proximal phalanx, palmar plate), the structures at risk (in particular, the neurovascular intermetacarpal and digital bundles), the flexor tendon(s) with possible synovitis, and the tissue to be released, usually the A1 annular pulley (and the A0 pulley if existing in long fingers), in coronal and sagittal planes. The thickness of the A1 pulley may be measured. The existence of an associated ganglion is observed (figure 1 and 2). All conditions that could possibly contra-indicate percutaneous trigger finger/thumb release are ruled out, including unexpected disease or anatomical abnormality. A dynamic evaluation of tendon gliding and of joint motion is performed under sonography. It is frequent to observe the phenomenon of triggering or altered gliding of the flexor tendons relative to each other or to the sheath. There may be abnormalities in the structure of the tendons themselves (figure 1 and 2).

The clinician proceeds then to local anesthesia, under sonography guidance, in the finger midline, from distal to

proximal, superficially, then deeply to the annular pulley to be released. The injection usually allows to better but transiently visualize the pulley to be released. Care is taken to avoid the injection of air which could alter sonographic imaging. The injection might be moderately painful, especially when performed into the flexor sheath, the patient should be averted of it just before this injection to avoid any unwanted movement. New dynamic sonographic imaging is then obtained, detecting subtle friction or triggering phenomenon not seen before the anesthesia. The painless active tendon(s) excursion can now be evaluated.

The clinician creates, at some distance from the structure to be released, the entry point for the subsequent introduction of the probe and of the SI-TF. This is done using the 14 Gauge catheter, under sonography guidance. The entry point through the flexor sheath is made just distal to the A1 pulley. The tip of the catheter is accurately identified by doing slight rotations of its bevel. After retrieval of the catheter, according to the preferences of the surgeon, a probe is used, or the SI-TF is directly inserted in the sheath. When the probe is used, it is introduced by its rounded extremity and allows to palpate the flexor tendon sheath and to make some room for the SI-TF. Sometimes it is so tight that there is not enough room for the probe, particularly in diabetic patients – the surgeon should not then forcefully introduce the probe.

After retrieval of the probe, the SI-TF is introduced through the entry point, under sonographic control, with the bevel of the instrument parallel to the skin (figure 3). Once the SI-TF is in the sheath, a 90° rotation of the instrument is performed, allowing to turn the bevel of the instrument in the sagittal plane, perpendicular to the pulley to be released (figure 4). The release is progressively performed by crocheting oscillating movements in the sagittal plane, from distal to proximal, in a retrograde manner (figure 5). The center of rotation of the alternating movements corresponds roughly to the entry point. The release is performed in the safe zone, that is in the palmar midline, at the apex of the pulley in the coronal plane with constant sonographic control of the adjacent neuro-vascular structures (coronal and sagittal planes) and of the instrument, highlighted by its sonographic markings (figures 5 and 6). In the thumb, special care is taken to locate the radial collateral digital nerve which is in some patients at risk when it is very mobile. The pathway of the nerve must be clearly identified and be put out of the SI-TF target before the release start. Some cracking sounds can be heard if the pulley is very thick.

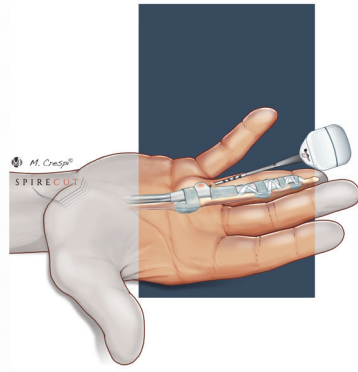


Figure 3

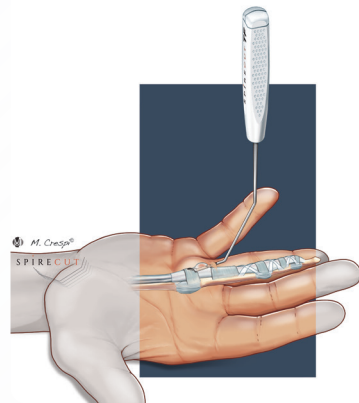


Figure 4

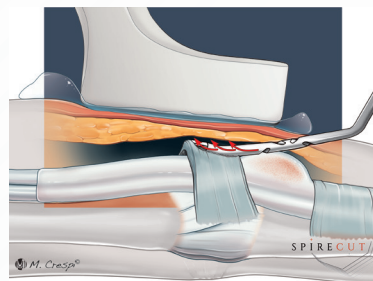


Figure 5

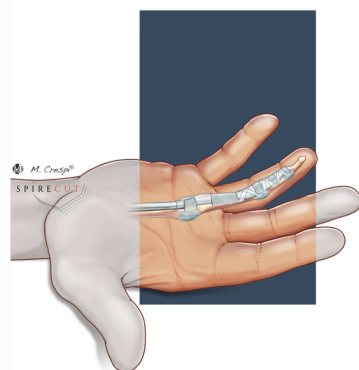


Figure 6

At the end of the procedure, after removal of the SI-TF, the probe can be re-introduced (or introduced for the first time if there was initially insufficient space) to evaluate the completion of the release - alternatively this check may be performed with the SI-TF tip by doing small and soft crocheting movements, just after the release. The probe or the SI-TF can be felt and seen displaced through the sectioned structure, up to the subcutaneous plane, without resistance. In long fingers, care must be taken that the A0 pulley is also completely released, particularly in the case of an associated Dupuytren with palmar nodes. The patient is now invited to actively mobilize the operated finger/thumb, and the clinician can observe clinically the disappearance of the triggering phenomenon, the restoration of normal tendon gliding and the integrity of the flexor tendons.

In case of multiple trigger digits, another SI-TF needs to be used for each operated finger/thumb as Spirecut's Sono-Instruments are single-use medical devices. Re-use may pose health and/or safety risks to the patient, including compromised cutting performance.

Carpal tunnel

The clinician repeats the pre-operative sonographic imaging of the palmar region of the distal forearm and wrist, now under sterile conditions, to make sure that he/she can well identify the anatomical structures representing important landmarks (distal radius and pronator quadratus, lunate, hook of hamate, scaphoid and trapezial tubercles, transverse carpal ligament), the structures at risk (in particular, the ulnar artery and superficial palmar arch, the ulnar and median nerves and branches, the flexor tendons), and the tissue to be released, that is the transverse carpal ligament (figures 7, 8, 9 and 10). The surface of the median nerve, usually enlarged at the entrance of the carpal tunnel, can be measured, and its structure and area within the carpal tunnel evaluated. The origin of the motor branch can be identified and any abnormality in origin and location of the motor branch is ruled out. Distally, the type of Berrettini anastomosis between median and ulnar nerve is determined, if it exists, and the branch is also accurately located to prevent an inadvertent iatrogenic laceration. Once again, all conditions that could possibly contra-indicate percutaneous carpal tunnel release are ruled out, including unexpected disease or anatomical abnormality. A dynamic evaluation of flexor tendon gliding can be performed under sonography, which helps in identifying the tendons and the median nerve. The safe zone of release is identified, ulnar to the median nerve and radial to the hook of the hamate, not too ulnar, to avoid entering Guyon's canal. Note that sometimes the ulnar pedicle (easily identified by the pulsating ulnar artery) is radial to the hook of the hamate; in this circumstance, the safe zone is quite limited, though local anesthesia may slightly displace radially the median nerve, making place for safe release by a phenomenon of hydro dissection.

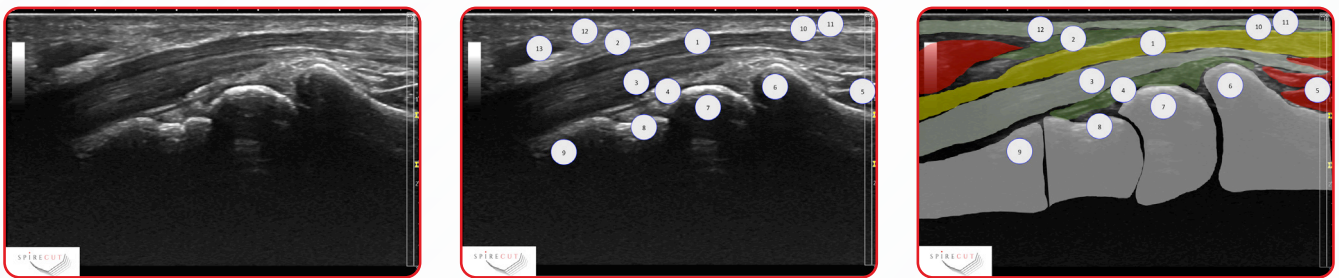


Figure 7 : Carpal tunnel, longitudinal view : 1 : Median nerve ; 2 : Transverse carpal ligament ; 3 : Flexor tendons ; 4 : Volar radiocarpal ligaments ; 5 : Pronator quadratus ; 6 : Distal radius ; 7 : Lunatum ; 8 : Capitatium ; 9 : Metacarpal bases ; 10 : Carpi volare ; 11 : Palmaris longus ; 12 : Palmar aponeurosis ; 13 : APB.

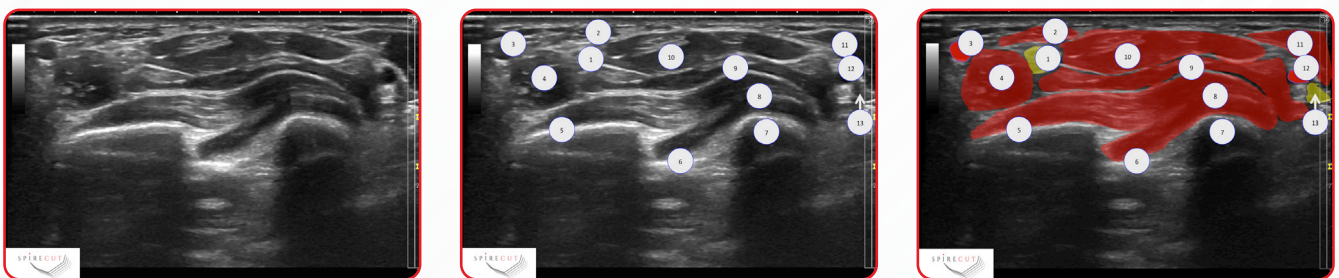


Figure 8 : Distal forearm, transverse view at level of Pronator quadratus : 1 : Median nerve ; 2 : FCR tendon ; 3 : Radial artery ; 4 : FPL ; 5 : Distal radius ; 6 : Interosseous membrane ; 7 : Distal ulna ; 8 : Pronator quadratus ; 9 : FDP ; 10 : FDS ; 11 : FCU ; 12 : Ulnar artery ; 13 : Ulnar nerve.

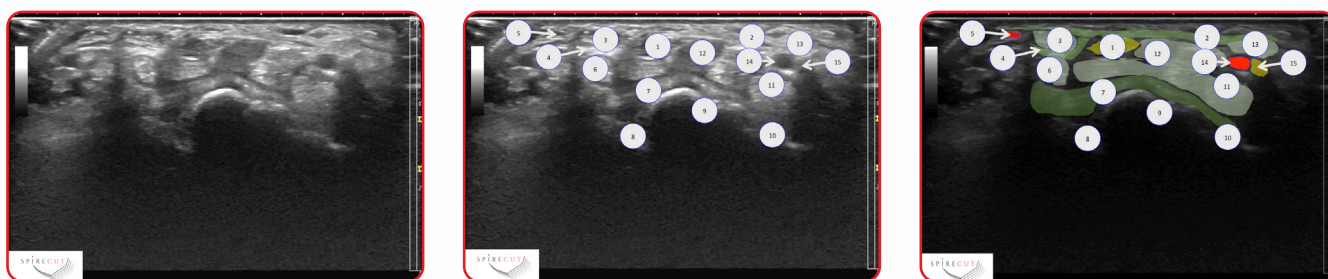


Figure 9 : Carpal tunnel, transverse view at level of triquetro-lunar joint : 1 : Median nerve ; 2 : Transverse carpal ligament ; 3 : FCR tendon ; 4 : FCR tendon sheath ; 5 : Superficial palmar branch of radial artery ; 6 : FPL ; 7 : Palmar radiocarpal ligaments ; 8 : Scaphoid ; 9 : Lunatum ; 10 : Triquetrum ; 11 : FDP ; 12 : FDS ; 13 : FCU ; 14 : Ulnar artery ; 15 : Ulnar nerve.

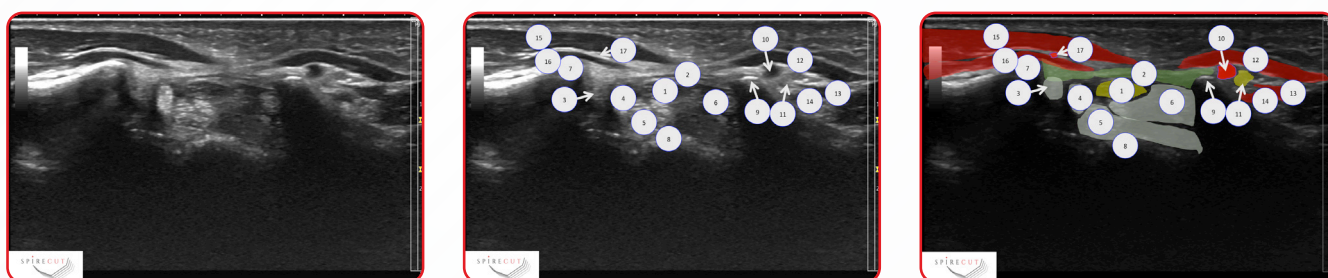


Figure 10 : Carpal tunnel, transverse view at level of second carpal row (trapezium and hamate levels) : 1 : Median nerve ; 2 : Transverse carpal ligament ; 3 : FCR tendon ; 4 : FPL ; 5 : FDP ; 6 : FDS ; 7 : Tubercle of trapezium ; 8 : Capitate ; 9 : Hook of hamate ; 10 : Ulnar artery ; 11 : Ulnar nerve ; 12 : ADM ; 13 : FDM ; 14 : ODM ; 15 : APB ; 16 : FPB ; 17 : Superficial palmar branch of radial artery.

The clinician proceeds then to local anesthesia, under sonography guidance, from proximal to distal, with injection of local anesthetic product first in the carpal tunnel, then superficially to the transverse carpal ligament. The needle entry point is just proximal to the carpal ligament, in the distal palmar forearm, ~1 cm proximal to the wrist flexion crease, ulnar to the Palmaris longus, in the safe zone previously identified. Care is taken to avoid the injection of air which could alter sonographic imaging. The injection might be moderately painful, especially in the superficial plane. As explained in the previous paragraph, the hydro dissection provided by the local anesthesia may displace radially the median nerve, helping the physician to protect it during the operation.

The clinician creates then the entry point for the subsequent introduction of the probe and of the SI. This is done using the 14 Gauge catheter, under sonography guidance. The tip of the catheter is accurately identified by doing slight rotations of its bevel. The catheter is introduced in the distal palmar antebrachial aponeurosis, 1 cm proximal to the volar wrist crease, in the safe zone between the hook of the hamate and the median nerve, with an inclination of about 35° in the sagittal plane.

After retrieval of the catheter, the probe is introduced in the carpal tunnel by its rounded extremity. This step allows to palpate under sonography the transverse carpal ligament to be released, from proximal to distal, to define the pathway of future section, to confirm the subsequent adequate position of the SI-CT, and to make some room for the SI-CT. The probe is placed just lateral to the hook of the hamate, relatively distant to the median nerve which remains radial to the probe. The physician makes sure that the probe cannot pass from the carpal tunnel to the subcutaneous plane. During this step, the sonography probe is placed alternately longitudinally and transversally, to obtain longitudinal and axial views, for perfect identification of the anatomical structures and position of the probe.

After retrieval of the probe, the SI-CT is introduced through the entry point, under sonographic control, with the bevel of the instrument parallel to the skin (figure 11). Once the SI-CT is under the forearm aponeurosis, a 90° rotation of the instrument is performed, allowing to turn the bevel of the instrument in the sagittal plane, perpendicular to the transverse carpal ligament to be released (figure 12). The release is progressively performed by crocheting oscillating movements in the sagittal plane, from proximal to distal, in an antegrade manner (figures 13 and 14). The center of rotation of the alternating movements corresponds roughly to the entry point. The release is performed in the safe zone, located just laterally to the hook of the hamate, with constant sonographic control of the ulnar artery location, of the median nerve, and of the SI-CT, highlighted by its sonographic markings, respectively. The section of the transverse carpal ligament is performed slightly obliquely, in a plane volar to dorsal and lateral to medial. All over the procedure, short axial views are regularly performed to control the position of the instrument. The distal border of the ligament is released with great care because of the close vicinity of the volar superficial carpal arch and of the motor and Berretini branches of the median nerve, by identifying accurately the instrument tip and the neurovascular structures under sonography. Some cracking sounds may be heard during the release (figure 15).

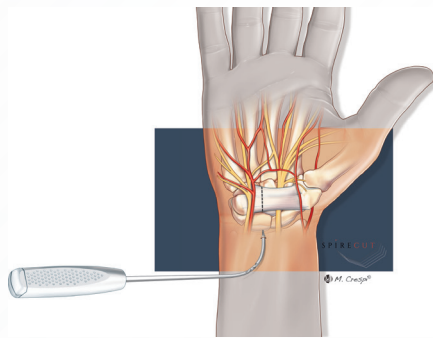


Figure 11

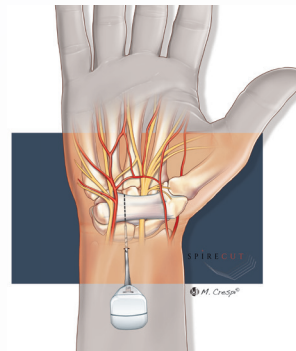


Figure 12

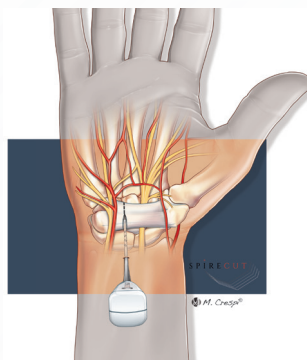


Figure 13

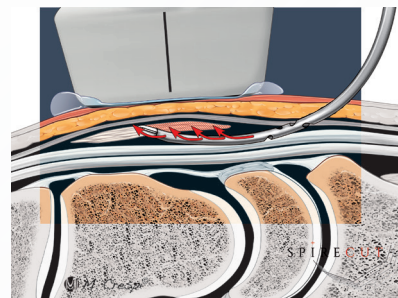


Figure 14

After removal of the SI-CT, the probe is re-introduced in the carpal tunnel and can be felt and seen displaced through the sectioned structure, up to the subcutaneous plane, without resistance (figure 16). If it is not the case, the SI-CT is reintroduced to release the remaining part of the transverse carpal ligament.

In case of bilateral surgery, another SI-CT needs to be used as Spirecut's Sono-Instruments are single-use medical devices. Re-use may pose health and/or safety risks to the patient, including compromised cutting performance.

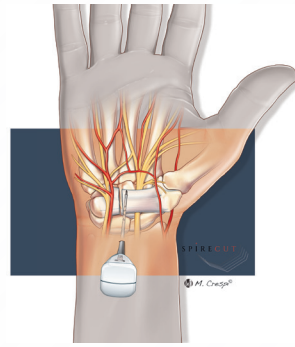


Figure 15

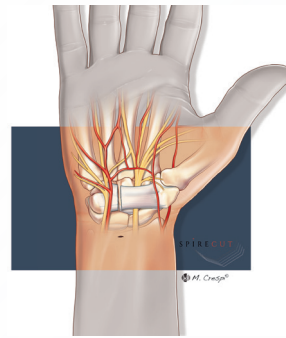


Figure 16

Postoperative Care

At the end of the procedure, if there is some blood oozing, it might be useful to prevent the formation of a hematoma by compressing the site of the release during five minutes. A compressive dressing is then applied, covering the site of introduction of the instruments and the site of the release. This dressing is usually removed twelve hours after the procedure, and no more dressing is then needed. The patient is allowed to wash his/her hand and to progressively resume his/her daily activities, the day after the procedure. The patient is advised to wear during a few days a sling to elevate the operated limb when he/she does nothing with his/her hand and to move actively his/her fingers, to prevent finger swelling and possible Complex Regional Pain Syndrome (CRPS). It is also recommended to avoid for some weeks heavy work. For the trigger finger (long fingers only), passive proximal interphalangeal hyperextension motion exercises are advised for the three first postoperative weeks to prevent postoperative flexion deformity.

After carpal tunnel release, the patient should be well informed that decreased gripping strength and pillar pain are usual during some weeks or months after the operation, as after open or endoscopic release. He/she should be advised to avoid forceful hand gripping activities with the wrist in palmar flexion.

As after some time there is no remaining scar, and as it is not unusual that the patient forgets the side/finger operated, it is of paramount importance to document well in the chart of the patient the operation performed, the finger(s) operated and the side of the surgery. It is also advised to keep a record of the sonography performed during the operation, with the name of the patient and the type of operation performed, including operated side.

Note - This typical operative protocol can be slightly modified according to the clinical situation and preferences of the treating physician and adapted to the individual needs of the patient and of his/her condition.

Ordering Information

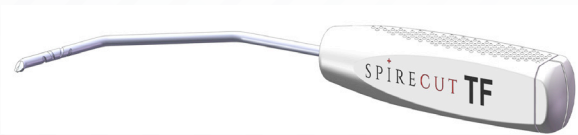

Product description

CT – Sono Instrument

Item number

KIT-SI-CT-01.01



Product description

TF – Sono Instrument

Item number

KIT-SI-TF-01.01

The single-use Sono-Instruments are disposed in a sterile kit, containing also a metallic probe, allowing to make space (carpal tunnel, flexor tendon sheath) before the release, and to check if the release is complete at the end of the procedure. The kit is in a blister, the latter in a carton box with the legal manufacturer label, reference number, Unique Device Identification (UDI) and the instructions for use. Kits are delivered in cardboard box with a dimension of 350x350x420mm (LxWxH). Content of one cardboard is 66 kits max. and will be adapted according to the quantities to deliver. US Federal Law restricts this device to sale by or on the order of a physician only.

SPIRECUT
Fribourg, Switzerland

Route de la Fonderie, 2,
CH-1700 Fribourg

+41 26 505 18 38

www.Spirecut.com

info@spirecut.com

